

# Giant adrenal incidentaloma – myelolipoma

Miltiadis Lalountas MD, PhD

## Corresponding author

Department of Surgery, General Hospital of Polygyros – Chalkidiki, Greece Hippokratous 5, Polygyros Chalkidiki 63100, Greece

Tel : +30 6974481181

E-mail : miltiadislalountas@yahoo.gr

Received Date: April 8, 2022

Accepted Date: April 19, 2022

Published Date: May 22, 2022

## Abstract

Adrenal myelolipomas (AMLs) are unusual non-functioning benign tumours composed of adipose and hematopoietic tissues. It is usually diagnosed accidentally and nowadays much more frequently because of widespread use of ultrasonography, computed tomography (CT) and magnetic resonance imaging. Adrenal myelolipoma is usually unilateral and asymptomatic, though known to be associated with obesity, hypertension, endocrinological disorders and some malignancies. We present a 48 years-old female patient, obese with no medical history and a painless right-sided mass. CT scan suggested the diagnosis of giant adrenal myelolipoma. The complete preoperative laboratory exams showed a non-functioning tumour. The patient underwent open right adrenalectomy and the pathological study confirmed the diagnosis of adrenal myelolipoma. AMLs discovered incidentally and CT scan remains the gold standard of diagnosis. The open surgery approach is the suggested treatment for giant AMLs (>10cm) while the laparoscopic and robotic surgery has been used in only a few cases.

## Key words:

Giant, asymptomatic, adrenal, myelolipoma, incidentaloma

## Clinical Image

Adrenal myelolipomas (AMLs) are unusual non-functioning benign tumours composed of adipose and hematopoietic tissues. It is usually diagnosed accidentally and nowadays much more frequently because of widespread use of ultrasonography, computed tomography (CT) and magnetic resonance imaging. Adrenal myelolipoma is usually unilateral and asymptomatic, though known to be associated with obesity, hypertension, endocrinological disorders and some malignancies. We present a 48 years-old female patient, obese with no medical history and a painless right-sided mass. CT scan suggested the diagnosis of giant adrenal myelolipoma (Fig 1). The complete preoperative laboratory exams showed

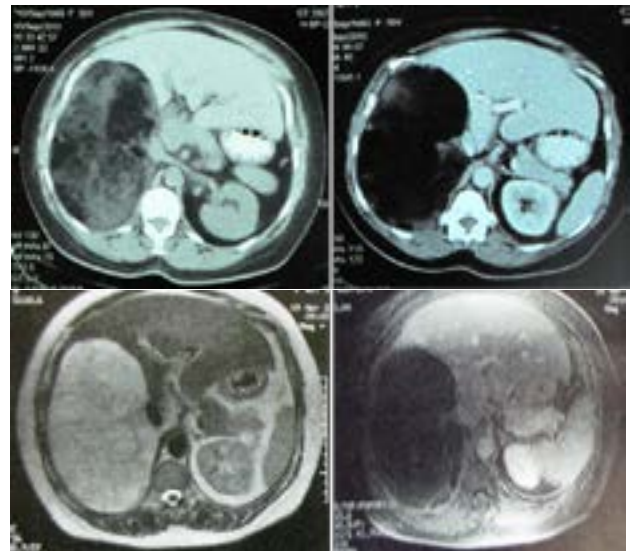
a non-functioning tumour. The patient underwent open right adrenalectomy (Fig. 2) and the pathological study confirmed the diagnosis of adrenal myelolipoma. AMLs discovered incidentally and CT scan remains the gold standard of diagnosis. The open surgery approach is the suggested treatment for giant AMLs (>10cm) while the laparoscopic and robotic surgery has been used in only a few cases.

## Figure 1

A,B: Axial CT image shows a giant heterogeneous fat tumor – adrenal incidentaloma, with pressure atrophy of the right liver's lobe and hypertrophy of the left one.

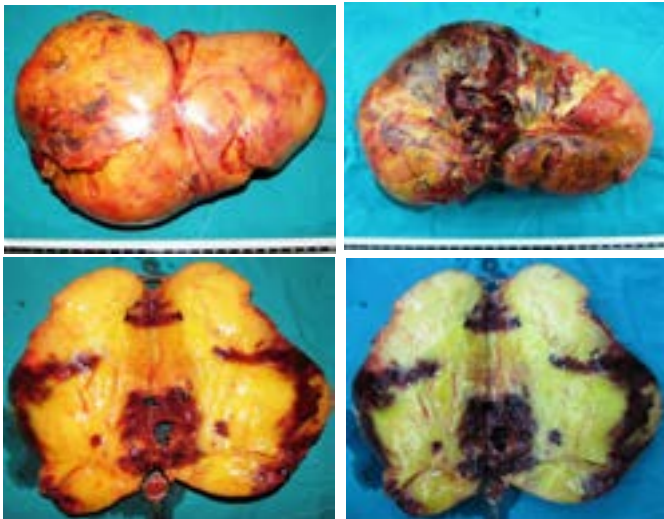
C,D: Axial MRI scan shows a giant fat tumor – adrenal incidentaloma with highlighted (T1 weighted image) and suppressed fat (T2 weighted image).

Figure 1. Abdomen CT scan shows a giant



**Figure 2**

A,B: Giant adrenal incidentaloma – myelolipoma (28x15x8cm, 1585gr). Frontside and backside of the surgical specimen. The capsule was intact and resolved during surgery. C,D: Cross section of the surgical specimen shows fat (yellow) and adipose (red) tissue.



## References

- Ramdani A, Aissaoui A, Bouhout T, Bennani A, Latrech H, Serji B, El Harroudi T. Giant symptomatic adrenal myelolipoma: A case report. *Ann Med Surg (Lond)*. 2022 Feb 9;75:103333. doi: 10.1016/j.amsu.2022.103333. PMID: 35198182; PMCID: PMC8844840.
- Singh BK, Arumugaswamy PR, Chumber S, Rathore YS. Giant secretory multifocal adrenal myelolipoma: a diagnostic dilemma. *BMJ Case Rep*. 2021 Jan 29;14(1):e239441. doi: 10.1136/bcr-2020-239441. PMID: 33514622; PMCID: PMC7849868.
- Kienitz T, Schwander J, Bogner U, Schwabe M, Steinmüller T, Quinkler M. Giant bilateral adrenal lipoma in a patient with congenital adrenal hyperplasia. *Endocrinol Diabetes Metab Case Rep*. 2021 Mar 31;2021:20-0204. doi: 10.1530/EDM-20-0204. Epub ahead of print. PMID: 33845451; PMCID: PMC8052563.
- Zulia YS, Gopireddy D, Kumar S, Singareddy A, Lall C. A Rare Case of Hemorrhagic Giant Adrenal Myelolipoma: Radiographic and Pathologic Correlation. *Cureus*. 2021 Aug 21;13(8):e17353. doi: 10.7759/cureus.17353. PMID: 34567893; PMCID: PMC8452227.
- Roger BR, Dhali A, Ramesh RS, Dsouza C. Giant Bilateral Adrenal Myelolipoma: Case Report. *Indian J Endocrinol Metab*. 2020 Nov-Dec;24(6):551-553. doi: 10.4103/ijem.IJEM\_737\_20. Epub 2021 Jan 12. PMID: 33643873; PMCID: PMC7906101.
- Longoria-Dubocq T, Torres-Aguilar R, Ruiz-Vega K, De Ayal-Hillmann R, Lopez- Enriquez R. A Rare Case of Congenital Adrenal Hyperplasia with Giant Adrenal Myelolipoma. *P R Health Sci J*. 2020 Jun;39(2):226-228. PMID: 32663923.
- Katsimantas A, Filippou D, Melloy A, Papanidis S, Ferakis N. Macroscopic Appearance of Giant Adrenal Myelolipoma During Laparoscopy: An Adjunct in Differential Diagnosis. *Cureus*. 2020 Jan 7;12(1):e6582. doi: 10.7759/cureus.6582. PMID: 32051795; PMCID: PMC7001128.
- Cochetti G, Paladini A, Boni A, Silvi E, Tiezzi A, De Verman- dois JAR, Mearini E. Robotic treatment of giant adrenal myelolipoma: A case report and review of the literature. *Mol Clin Oncol*. 2019 May;10(5):492-496. doi: 10.3892/mco.2019.1823. Epub 2019 Mar 12. PMID: 31007910; PMCID: PMC6467000.
- Liu Q, Wang LA, Su J, Tong D, Lan W, Wang L, Liu G, Zhang J, Zhang VW, Zhang D, Chen R, Zhu Q, Jiang J. Giant bilateral adrenal myelolipomas in two Chinese families with congenital adrenal hyperplasia. *Endocr Connect*. 2018 Sep 1;7(11):1136-41. doi: 10.1530/EC-18-0273. Epub ahead of print. PMID: 30352423; PMCID: PMC6215793.
- Gupta SS, Kupfer Y. Giant Bilateral Adrenal Myelolipoma. *Balkan Med J*. 2017 Sep 29;34(5):476-477. doi: 10.4274/balkanmedj.2016.1749. PMID: 28990930; PMCID: PMC5635638.
- Campos Arbulú AL, Sadava EE, Kerman J, Fernández Vila JM, Mezzadri NA. Mielolipoma adrenal gigante. Adrenalectomía derecha laparoscópica [Giant adrenal myelolipoma. Right laparoscopic adrenalectomy]. *Medicina (B Aires)*. 2016;76(4):249-50. Spanish. PMID: 27576286.
- Park BH, Lee SL, Seo KJ, Bae SR, Lee YS, Kang SH, Han CH. Laparoscopic hand- assisted adrenal sparing surgery for a giant adrenal myelolipoma: A case report. *Int Surg*. 2015 May 19. doi: 10.9738/INTSURG-D-14-00289.1. Epub ahead of print. PMID: 25990775.
- Alvarez JF, Goldstein L, Samreen N, Beegle R, Carter C, Shaw A, Ben-David K. Giant adrenal myelolipoma. *J Gastrointest Surg*. 2014 Sep;18(9):1716-8. doi: 10.1007/s11605-014-2553-x. Epub 2014 Jun 3. PMID: 24889790.
- Gautam SC, Raafat H, Sriganesh S, Zaffar I, Olude I, Komolafe F, Qazi F. Giant adrenal myelolipoma. *Qatar Med J*. 2013 Nov 1;2013(1):7-11. doi: 10.5339/qmj.2013.2. PMID: 25003051; PMCID: PMC3991056.

15. Iglesias FJ, González JM, Jaime MT, Antequera EH. Mirolipoma suprarrenal gigante [Giant adrenal myelolipoma]. *Cir Esp*. 2011 Jan;89(1):55. Spanish. doi: 10.1016/j.cire-sp.2009.09.011. Epub 2009 Nov 3. PMID: 19889402.
16. Fernandes GC, Gupta RK, Kandalkar BM. Giant adrenal myelolipoma. *Indian J Pathol Microbiol*. 2010 Apr-Jun;53(2):325-6. doi: 10.4103/0377-4929.64314. PMID: 20551546.